



Toxicities induced by CMF chemotherapy in Rabbits

Aziza Khanam

Dept. of Biochemistry, Al-Tibri Medical College Karachi, Isra University, Pakistan

Received: 28-06-2014 / Revised: 10-08-2014 / Accepted: 21-08-2014

ABSTRACT

Chemotherapeutic agents are used for the treatment of cancer. These cytotoxic agents produce hematological & hepatic toxicities. This study is aimed to assess the toxicities induced by CMF (Cyclophosphamide Methotrexate and 5-fluoro – uracil) on liver and kidney. The study was conducted on female rabbits. The animals were grouped into four groups. One group was treated with CMF. The second group was treated with Tamoxifen. The third group was treated with CMF and Tamoxifen where as the fourth group was not treated with any drug and considered as control. The rabbits treated with CMF and Tamoxifen have shown increased level of AST and ALT as compared to control rabbits and the rabbits that received six CMF cycles. Lactate dehydrogenase (LDH) was also increased in CMF and Tamoxifen treated rabbits as compared to control rabbits. The histopathological changes in CMF and Tamoxifen treated rabbits had shown liver oedema, portal infiltration and fibrosis, where as kidney mesangial cell proliferation was (71.4%) also observed in rabbits treated with CMF & Tamoxifen.

Keywords: CMF, Tamoxifen, chemotherapy, toxicities, cancer.



INTRODUCTION

Chemotherapy is used for the treatment of cancer, either alone or as an adjuvant to surgery, radiotherapy and endocrine therapy. In breast cancer treatment, combination therapy is superior as compared to single agent therapy. Many cytotoxic drugs are associated with side effects (1). The drug CMF (combination of Cyclophosphamide, Methotrexate and 5-Fluorouracil) is used for the treatment of breast cancer. Overall 40-50% of patients respond to treatment (2). Tamoxifen is an antiestrogen, which acts at the level of steroid receptors rendering it refractory to estrogenic stimulation(3), estrogen receptors positive patients are likely to respond Tamoxifen (4), whereas only 10% of estrogen receptor negative patients respond to Tamoxifen. Tamoxifen is used as an adjuvant in the treatment of early breast cancer patients, which proved to be associated with side effects. Tamoxifen hepatotoxicity is uncommon and is assessed by case histories & reports from clinical trials. In previous reports, the tamoxifen induced liver diseases are essentially steatosis and cholestatic syndrome (5). The majority of medical oncologists prefer to use CMF for the treatment of breast cancer patients. Most of the breast cancer patients

develop hematological or hepatic complications during the treatment, which may be either due to cytotoxic agents used in chemotherapy or due to disease processes. Some chemotherapeutic agents are cleared by the liver, where as others produce significant liver dysfunction (6). In addition to typical hepatocellular injury, cholestasis and hepatic sinusoidal obstruction syndromes are also common & sometimes may lead to cirrhosis (7). Liver injury secondary to cytotoxic chemotherapy is the serious adverse effect of anticancer treatment. Our knowledge about the effect of chemotherapeutic drugs is not complete (8). So basic laboratory methods are used in this study to assess the hepatotoxicity on animal models due to cytotoxic chemotherapeutic agents. In the present study the cytotoxic drugs were assessed by treating the female rabbits with CMF and Tamoxifen and then the toxicities developed by these drugs were analyzed.

MATERIAS and METHODS

Ethical guidelines: The experiments were conducted with ethical guidelines of institutional ERB (Ethical Review Board) and internationally accepted principles for laboratory use and care in

animal research (Health research extension Act of 1985).

Study design: The study was conducted on female rabbits. They were placed at room temperature and the weights of animals were taken before and after the therapy (i.e after the interval of three weeks and after completion of treatment). Experimental animals were classified into the following groups.

- A. CMF (Cyclophosphamide, Methotrexate and 5 – Fluorouracil) treated group.
- B. Tamoxifen treated group
- C. CMF + Tamoxifen treated group
- D. Control.

Drug administration

A combination therapy CMF containing cyclophosphamide, Methotrexate and fluorouracil was given intravenously in the ear vein of rabbits. The dose were

Cyclophosphamide	20 mg/kg body weight of rabbit
Methotrexate	1 mg/kg
5-fluorouracil	15 mg/kg

Group A: CMF was injected I/V in the ear vein of rabbits after interval of 3 weeks (Six cycles).

Group B: The rabbits were administered Tamoxifen orally in the doses of 0.4 mg/kg body weight of rabbit/day. This dose was given up to 15 weeks.

Group C: CMF was injected I/V in the ear vein of rabbits after the interval of 3 weeks (six cycles). During therapy Tamoxifen was given orally 0.4 mg/kg body weight of rabbit/day.

Group D: The rabbits were given no drugs and considered as control. The rabbits were placed in the same environment and on same diet as provided for drug administered groups up to 15 weeks.

Collection of sample:

- i. The blood samples of A and C group were collected after 6 cycle of CMF by cardiac puncture.
- ii. The blood samples of group B and D animals were collected by cardiac puncture after 15 weeks.

After completion of therapy the animals were sacrificed and their liver and kidneys were collected for histopathological examination. The blood samples of all groups were analyzed for hepatic parameters; Bilirubin was estimated by kit method supplied by Human Company (Germany). Alkaline phosphatase and transaminases were estimated by kit supplied by Biomerieux (France). LDH, by sigma diagnostic kit and uric acid was estimated by Bauer & Ackermann method (9).

Statistical Analysis: Results are presented as mean \pm SD statistical significance from control & test, values evaluated by student t test, statistical probability of $p < 0.05$ was considered significant.

RESULTS

Table – I represents the initial and final weight and mortality rate of rabbits. The mortality rate of CMF treated rabbits is very high (60%). Table – II shows the hepatic parameters of rabbits. The serum Aspartate transaminase (AST) and serum Alanine transaminase (ALT) were significantly increased in CMF and Tamoxifen treated rabbits as compared to control rabbits and the rabbits treated only with CMF. The level of LDH was higher in rabbits treated with CMF and Tamoxifen as compared to control rabbits. Table – III shows the histopathological changes in the CMF and Tamoxifen treated rabbits. It was found that the rabbits who were treated with CMF had shown higher toxicities in terms of liver dysfunction but the kidney mesangial cell proliferation was maximum in rabbits who had got the treatment of both CMF and Tamoxifen. Fig 1 to 7 shows the histopathological changes in liver & kidney.

DISCUSSION

Chemotherapy is appropriate for treatment of certain tumors, in which the complete response rates are high and where prolongation of survival and cure are often possible (10). The chemotherapy used in the treatment of breast cancer (CMF and Tamoxifen) develops certain hematological or hepatic complications during their treatment due to side effects of the cytotoxic drugs. In the present study we tried to explore some insights by observing different stages of toxicities observed in animals after the administration of chemotherapeutic drugs, CMF and adjuvant Tamoxifen. There is no significant difference in the levels of hepatic parameters of rabbits who received six cycles of CMF as compared to the control rabbits. So CMF doesn't produce considerable toxicities. Kumar and Clark (11), also reported that the immediate response of these drugs when given simultaneously does not present an established picture of toxic hepatic pathology, but the ultra changes of different hepatic parameters show that these changes may lead to cirrhosis. Beer et al (12) had found that dose reductions of CMF and bone marrow toxicity were statistically significantly correlated with the endogenous creatinine clearance. Leucopenia, febrile neutropenia, nausea and cardiac toxicity in breast cancer patients after CMF administration was reported (13). Tamoxifen is a widely used effective and tolerated agent in the treatment of primary and

recurrent breast cancer. In the adjuvant setting Tamoxifen decreases the recurrence and death by 25% and 16% respectively. The toxicities of Tamoxifen are of minor concern. In the present study the mortality rate of Tamoxifen treated rabbits was 20% & the level of ALT was also increased as compared to control rabbits. So it seems that mild hepatotoxicity is present according to Tarantino et al (14), severe hepatotoxicity is rare complication due to Tamoxifen. Tamoxifen treatment resulted in the induction of premature condensation, chromosomes breakage and improper mitotic spindle formation in the hepatocytes of rats (15). In humans Tamoxifen causes liver dysfunction. Pratt et al. (16) reported elevated levels of aminotransferase and fatty liver after the administration of Tamoxifen. Wada et al. (17) observed Tamoxifen side effects as renal cell carcinoma, nausea, vomiting & liver dysfunction. Tamoxifen is often associated with antiestrogenic effects such as hot flushes & vaginal dryness and endometrial proliferation in post menopausal women (18). The changes in hepatic enzymes and

microscopic alterations in the cells of CMF and Tamoxifen treated rabbits lead to necrosis of hepatocytes and finally cirrhosis is produced. Van et al. (19) had reported hepatotoxicity and a liver biopsy revealed a grade 11 toxic hepatitis during adjuvant chemotherapy with CMF in breast cancer patients.

CONCLUSION

It is concluded that CMF and Tamoxifen are toxic for liver and kidney, and cancer patients undergoing cytotoxic chemotherapy require careful assessment of liver function & renal function both prior to and during therapy.

Acknowledgment

The courtesy and help extended by Dr. Qamar Jamal Department of Pathology, Jinnah Postgraduate Medical centre, Karachi for histopathology are gratefully acknowledged

Table – I: Weight And Mortality Rate Of Control And Drug Treated Rabbits

Animal groups	Initial weight (kg)	Final weight (kg)	Mortality rate
Control	1.44 ±0.05 (7)	1.50 ±0.05 (6)	14.28% (1/7) ⁺
CMF treated rabbits	1.49 ±0.06 (15)	1.50 ±0.03 (6)	60.00% (9/15)
CMF and Tamoxifen treated rabbits	1.28 ±0.03(15)	1.29 ±0.04 (7)	53.33% (8/15)
Tamoxifen treated rabbits	1.40 ±0.07 (10)	1.26 ±0.06 (8)	20.00% (2/10)

⁺Percentage of animals died during experiment (Number of dead animals/Total number of animals).

Table – II : HEPATIC PARAMETERS OF CONTROL RABBITS AND RABBITS RECEIVED DRUG TREATMENT

Hepatic parameters Group	Control (D)	Rabbits received Six I/V CMF cycles (each cycle/3 weeks) (A)	Tamoxifen treated rabbits (15 weeks) (B)	Six cycles I/V CMF and Tamoxifen treated rabbits (C)
Total Bilirubin (mg/dl)	2.29 ±0.14 (7)	2.46 ±0.14 (6)	2.45 ±0.10 (6)	2.32 ±0.14 (7)
Direct Bilirubin (mg/dl)	2.13 ±0.07 (7)	2.08 ±0.06 (6)	2.15 ±0.13 (6)	1.95 ±0.09 (7)
Serum Aspartate transaminase (U/ml)	48.20 ±2.53 (7)	41.25 ±5.07 (6)	48.64 ±5.28 (6)	85.00 ±10.15 (6) ^{ab*}
Serum Alanine transaminase (ALT) (U/ml)	41.00 ±2.76 (7)	48.30 ±4.50 (6)	60.35 ±5.57 (6)*	67.50 ±5.08 (6)*
Serum Alkaline phosphatase (U/L)	107.00 ±3.52 (7)	120.00 ±8.56 (6)	114.90 ±2.49(6)	80.00 ±17.42 (7) ^a
Serum Lactate dehydrogenase (B-B U/ml)	271.42 ±18.49 (7)	380.00 ±51.36 (5)*	405.00 ±102.51(6)*	364.00 ±27.01 (5)*
Serum Uric acid (mg/dl)	2.07 ±0.13 (6)	2.28 ±0.09 (6)	2.63± 0.09 (6)*	2.46 ±0.15 (7)*

*p< 0.05 as compared to control rabbits.

a. p<0.05 as compared to rabbits received six CMF cycles. b. <0.05 as compared to Tamoxifen treated rats

Table – III: HISTOPATHOLOGIC CHANGES IN THE CMF AND TAMOXIFEN TREATED RABBITS

Histopathological Parameters	Total toxicities after six cycles of CMF treatment (each cycle /3weeks)	Total toxicities after six cycles of CMF and Tamoxifen treatment
(1) Liver Congestion edema Portal infiltration Fibrosis	33.33% (2/6)+ 66.66% (4/6) 66.66% (4/6) 66.66% (4/6)	28.57% (2/7) 42.85% (3/7) 28.57% (2/7) 42.85% (3/7)
(2) Kidney Mesengial cell proliferation	33.33% (2/6)	71.42%(5/7)

+Percentage (Number of rabbits having toxicity /Total number of rabbits)

Figure: 01: Liver with portal tract. The portal tract is expanded shows dilated portal vein, bile duct proliferation and lymphocytic infiltration

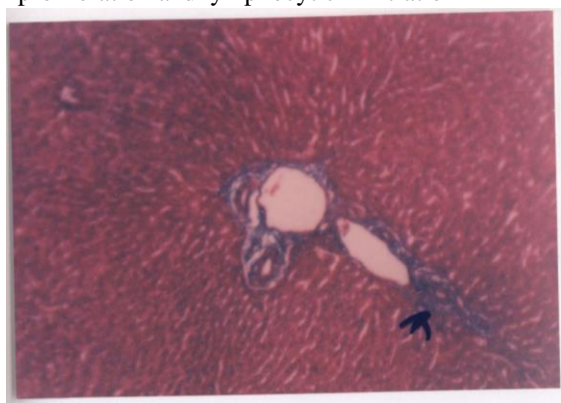


Figure: 02: Liver with portal tract. A portal tract with dilated vein, ducts and fibrous tissue which is stained green

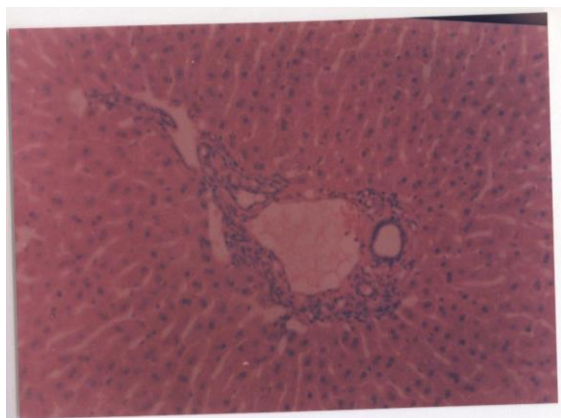


Figure : 03: Liver showing portal fibrosis and dilated portal vein.

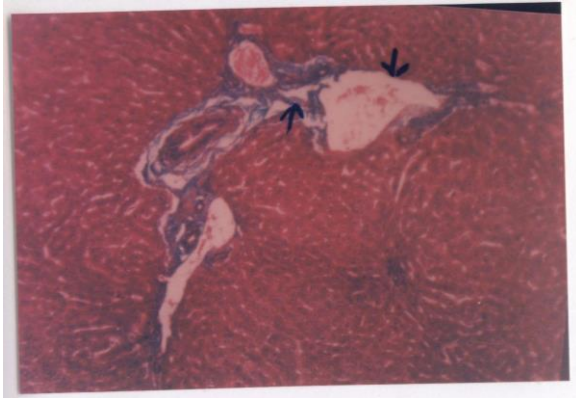


Figure: 04: Liver with dilated and congested vein with early thrombosis

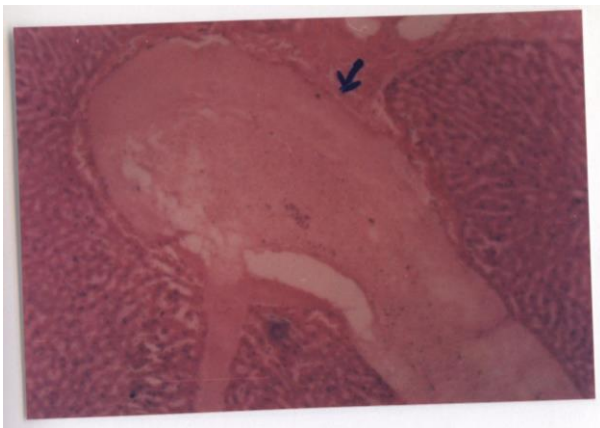


Figure: 05: Liver showing a portal tract. There is vascular congestion and cell infiltration.

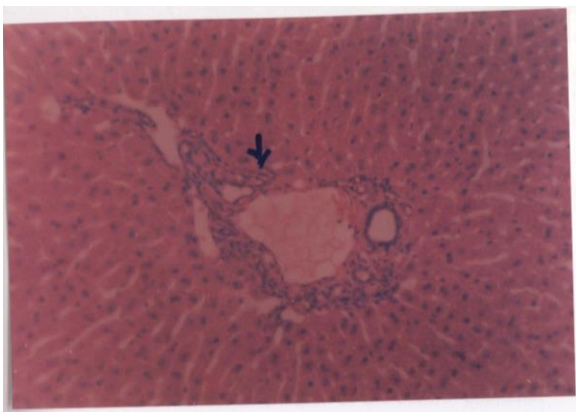


Figure : 06: Kidney showing parenchyma and interstitial cells.
There is mild mesangial cell proliferation of glomerular cells.

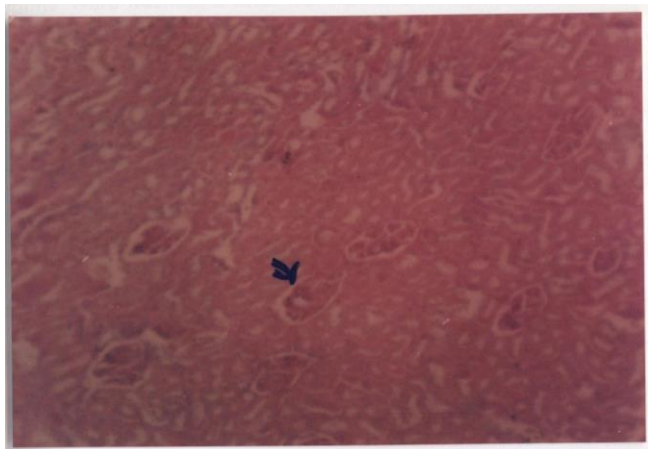
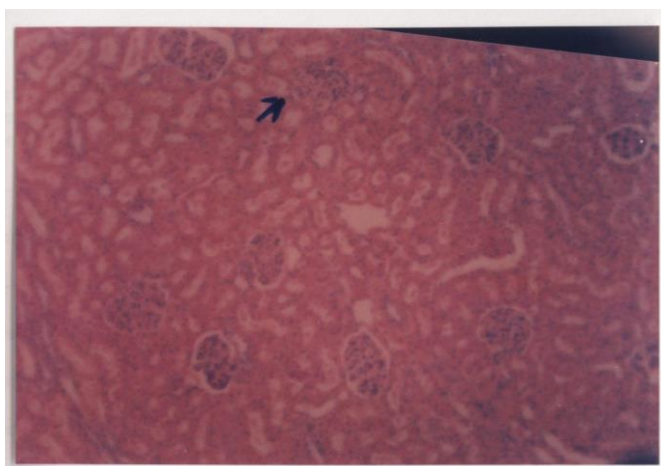


Figure: 07: Kidney showing renal glomeruli.



REFERENCES

1. Bonadonna, G. and Robustellidella Cunna, G. Hand book of Medical Oncology. Translated from 3rd Italian edition from Sharon Krengel. 1988; Pp 407, 409-410.
2. Bonadonna, G. Rossi, A. and Valagussa, P. The CMF program for operatable breast cancer with positive axillary nodes. *Cancer*. 1977 ; 39:2904-2915.
3. Fabian, C; Sternson and Barnett. Clinical pharmacology of Tamoxifen in patients with breast cancer. Comparison of traditional and loading dose schedules. *Cancer Treat. Rep.* 1986; 64: 765-773.
4. Cuning, F. J; Gray, R. and Davis, T.E. Tamoxifen vs. placebo double blind adjuvant trial in elderly women with stage 2 breast cancer. *NCI Monographs*. 1986; 1: 119-123.
5. Lasso De Laveage Mc, Zapater P, Such J, Solavera J. Paya, A. Horga JF et al. Tamoxifen hepatitis associated with Tamoxifen use. A case report & literature review. *Gastroenterol Hepatol*. 2002; 25: 247-250.
6. Ameet V, Thattschett, Nicholas Agrest, Christopher, Bo' Brien. Chemotherapy – induced Hepatotoxicity clinics in liver Disease. 2013 ; 17(4): 671 – 686
7. Thatishetty, A. V, Agresti N., O, Brien C, B. Chemotherapy induced hepatotoxicity. *Clin. Liver Dis*. 2013; 17 (4): 671-686.
8. Maor, Y. and Malnick, S. Liver injury induced by anticancer chemotherapy and Radiation therapy. *International J. of Hepatology*. 2013; Article ID:815105, 8 pages.
9. Baur, J. and Ackermann, P.G. *Clinical laboratory Method*, 8th edition, saint Louis, C.V. Company. 1974; Pp 396.
10. Karol, S. and Halnan, K.E. *Treatment of cancer*, 2nd edition, Chapman and Hall Ltd. 1999; Pp 139,374.

Khanam, World J Pharm Sci 2014; 2(9): 981-987

11. Kumar, P. and Clark, M. Liver biliary tract and pancreatic disease in: Clinical Medicine – A text book for Medical Student and Doctors; 3rd edition – Bailliere Tindall. 1994; Pp 260.
12. Beer Lv, Hermus AR, Pieters GF, Van Hoesel QG, Nooy MA, Mignolet F. Dose intensity of chemotherapy with cyclophosphamide, Methotrexate and 5 – fluorouracil in the elderly with advanced breast cancer. Eur. J. Cancer. 1992; 28(2-3): 686-90.
13. De Maio E, Gravina, A, Pacilio, C, Amabile G, Labonia V, Landi G, Nuzzo F, Rossi, E, D Aiuto G, Capasso I, Rinaldo M, Morrica, B, Elmo. M, Di Maio M, Perrone F, de Matteis A. Compliance and toxicity of adjuvant CMF in elderly breast cancer patients: a single center experience. BMC cancer. 2005; 24; 5(1):30.
14. Tarantino G, Di Minno MN, Capone D. Drug induced liver injury: is it somehow foreseeable. World J. Gastroenterol. 2009;15:2817-33.
15. Sargent, L. M., Dragon, Y.P, Balnut, N., Wiley, J.E, Salterr, C.A., Schroeder, P., Sattler, G. L., Jordan, V. and pilot, H.C. Tamoxifen induce hepatic aneuploidy and mitotic spindle disruption after a single in vivo administration to female Sprague dawley rats. Cancer Res. 1994; 54(13): 3357-3360.
16. Pratte, D.S. Knox, and Erban J. Tamoxifen induced steatohepatitis. Ann. Int. Med. 1995; 123(3): 236.
17. Wada, T. Nishiyam, K., Maeda, M. Hara, S. Taneka, N., Yasutomi, M. and Kunita, T. Combined chemoendocrine treatment with tegafur and tamoxifen for advanced renal cell carcinoma. Cancer. 1995; 15(4): 1581-84.
18. Morgan, M.A Ginchaermau, Y. and Mikuta. J.J. Endometriosis and Tamoxifen therapy. Int. J. Obstt. 1994; 35(1): 55-57.
19. Van outryVe. S, Schrijvers D, Van den Braude J, Wilmes P, Bogers J, Van Mark E, Vermosken JB. Methotrexate associated liver toxicity in a patient with breast cancer. Neth. J. Med. 2002; 60(5): 216-22.